

# Applications and Present Issues of Tomosynthesis in Spine Surgery

## 87th Annual Meeting of the Japanese Orthopaedic Association—Evening Seminar 4

Professor and Chairman  
Department of Orthopaedic Surgery  
Tokyo Women's Medical University  
**Yoshiharu Kato**



Yoshiharu Kato,  
M.D., Ph.D.

For the 87th Annual Meeting of the Japanese Orthopaedic Association (from May 22 to 25, 2014) Shimadzu and the association jointly held the evening seminar on the 23rd. We invited Shoichi Ichimura, M.D. (Professor, Department of Orthopaedic Surgery, Kyorin University School of Medicine) to chair the seminar and Yoshiharu Kato, M.D., Ph.D. (Professor and Chairman of the Department of Orthopaedic Surgery at the Tokyo Women's Medical University) to give a presentation entitled Applications and Present Issues of Tomosynthesis in Spine Surgery. The following is a description of what was discussed at the seminar.

### 1. Introduction

Today I will talk about applications and present issues of tomosynthesis in spine surgery. Actually, Shimadzu has offered tomosynthesis ("TS" below) systems since about 2003 and reportedly has sold over 400 units so far. This system was initially designed as an X-ray fluoroscopy system for gastrointestinal examinations. Therefore, it is most commonly used for upper gastrointestinal tract X-ray examinations. Most medical universities in Japan have one, so when you return to work you may be surprised to discover that your radiology department already has a Shimadzu tomosynthesis system. However, orthopedic surgeons started becoming aware of these systems only in about 2010, so there may still be many orthopedic surgeons that are unfamiliar with tomosynthesis.

Today I will first compare TS to plain radiography and CT in terms of performing spine surgery to treat cervical and lumbar spine disorders (Fig. 1). Specifically, I will refer to disorders such as OPLL and RA. The most valuable use for TS is evaluating images involving spinal instrumentations. It is especially useful for evaluating bone fusion after PLF or PLIF or screw loosening by using the

T-smart, which specifically eliminates metal artifacts. In addition, I will talk about both TS and SLOT radiography starting to be used in conjunction for sagittal alignment applications. This is extremely useful for measuring the angle of the pelvis and spine.

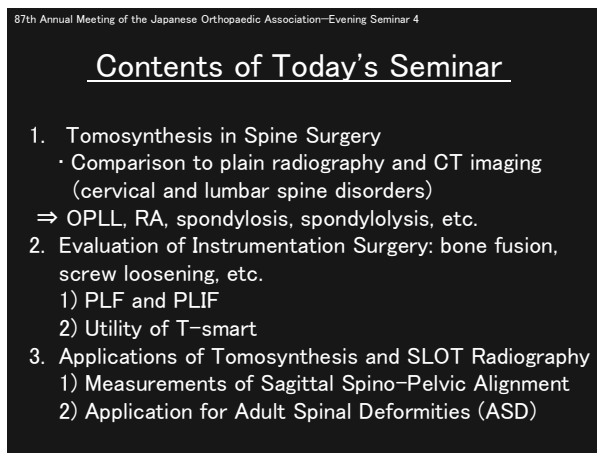


Fig. 1

### 2. Tomosynthesis (TS)

Essentially, TS images are nicer looking versions of what used to be called "tomography" images. They use lower X-ray exposure levels and extremely short scanning times. Since images are spaced 3 mm apart, it provides good visibility of the upper cervical vertebrae and cervicothoracic junctions, which are difficult to see using plain radiography. It allows clearly seeing vertebral body osteophytes, spondylosis, ligament ossification, and so on (Fig. 2). The lateral view also clearly shows the right and left facet joints. Though it does not provide the detail of CT imaging, it requires much lower X-ray exposure levels and shows positional relationships and shapes better than plain radiography.

In fact, there is published research that indicates the effective dose of TS is between 1/10 and 1/15 the level of CT, based on the assumption that the

thoracic spine is comparable to the chest and the lumbar spine is comparable to the abdomen (Fig. 3). Since reducing X-ray exposure levels is very important, it is also extremely important to understand what can be accomplished with TS so that the CT usage rate can be minimized.

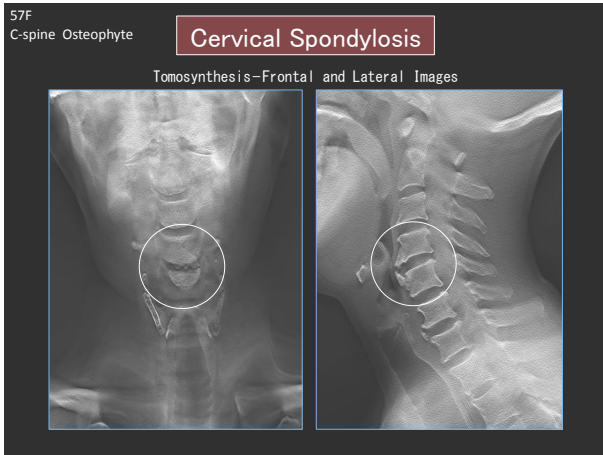


Fig. 2

87th Annual Meeting of the Japanese Orthopaedic Association—Evening Seminar 4

### Radiation Exposure (Effective Dose)

	TS	MDCT
Chest (mSv)	0.92	15.0
Abdomen (mSv)	1.12	12.9
Hip joint (mSv)	0.82	10.5

Effective dose

Koyama S *et al.*: Radiation dose evaluation in tomosynthesis and C-arm cone-beam CT examinations with an anthropomorphic phantom. Med. Phys. 37(8),4298-4306, August 2010

Fig. 3

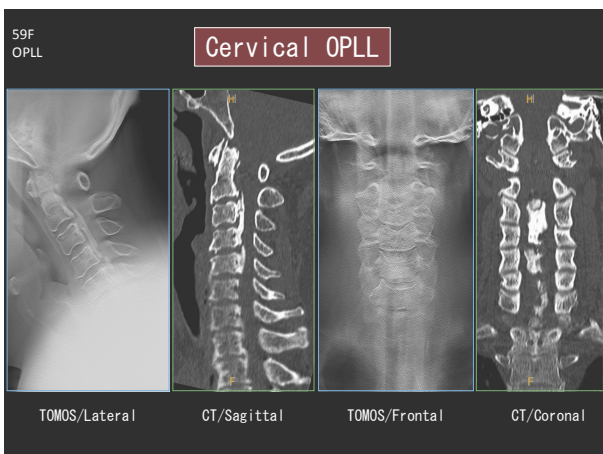


Fig. 4

For OPLL, the TS lateral view shows the positional relationship between facet joints and whether the OPLL is spreading toward the left or right. However, TS spatial resolution in the depth (anterior-posterior)

is not as good as with CT. Therefore, the OPLL is obscured in the frontal image (Fig. 4). In many cases, the vertebral body trabecula and facet joints are easier to see with TS than using CT. Therefore, TS could be used to evaluate osteoporosis and bone fractures, but there is a limit to how well TS can capture thin OPLL in the frontal view. CT is valuable because it can capture transverse images, but the high exposure dose levels must be kept in mind when using CT.

## 2.1 Cervical Vertebrae

Fig. 5 shows a TS image of cervical vertebrae with rheumatoid arthritis. Though it is not a typical case, it shows the upper cervical vertebrae sufficiently well. Though it is not as good as CT, TS does show a certain amount of deformities in rheumatoid arthritis, a difference between right and left facet joints, or a C<sub>0</sub>-C<sub>1</sub> (atlantooccipital joint) morphology.

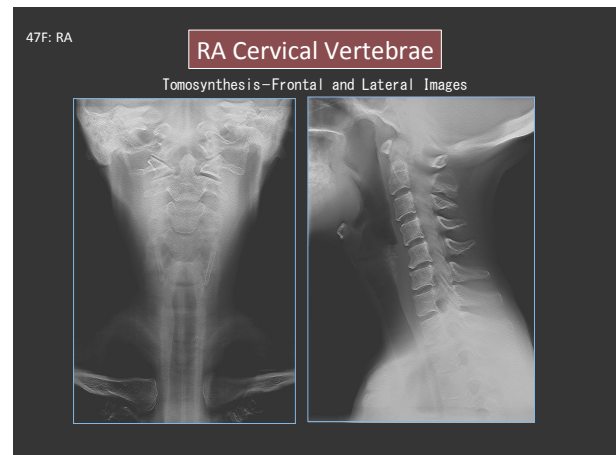


Fig. 5

87th Annual Meeting of the Japanese Orthopaedic Association—Evening Seminar 4

### Summary for Cervical Vertebrae

	Plain Radiography	TOMOS	CT
Fine Detail	×	○	◎
3D Visualization	×	○	◎
Axial Images of Spine	×	×	◎

(It provides both right and left sides of vertebrae with single scan but no axial images.)

- Superior for rendering lesions and so on in the upper cervical vertebrae, cervicothoracic transition area, and other areas.
- Shows OPLL, cervical spondylosis, and other lesions and allows confirming their positions.
- \* CT is superior for rendering c-spine OPLL in frontal view.

Fig. 6

Fig. 6 shows a summary for the cervical vertebrae. CT is better for viewing changes in more detail, but TS is probably better for trabecula and other areas. CT is superior for 3D imaging and the fact that axial images can only be viewed using CT. However, TS allows right-left comparisons from a single scan

and, though axial imaging is not possible, TS provides a certain amount of 3D understanding. Of course, TS is far superior to plain radiography for areas where plain radiography is poorly suited, such as the upper cervical vertebrae or the cervicothoracic transition area. However, it should be used with the understanding that visibility is poor in some areas, such as the frontal images of OPLL.

### 2.2 Lumbar Vertebrae

Next we'll discuss lumbar vertebrae. Compared to lateral images of plain radiography, TS better shows changes in the right and left sides of vertebral bodies and facet joints. If used properly for myelography, TS can show more detail in compressions or other features of the nerve root or spinal canal. **Fig. 7** shows an example of spinal canal stenosis (SCS) in the lumbar spine. Classification of vertebral disc vacuum is often attempted in such cases, but it is risky to make that judgment based on plain radiography alone. However, using CT merely to obtain a 3D understanding seems like a lot of trouble. TS is able to show vacuum phenomena clearly using a tenth of the X-ray exposure dose required for CT and it also provides an easy and effective means of obtaining a 3D understanding.

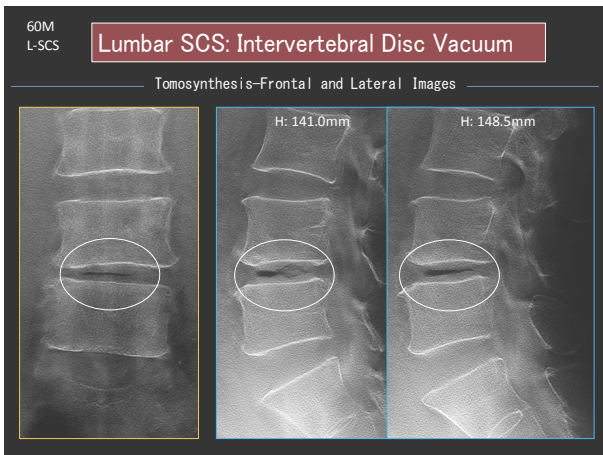


Fig. 7

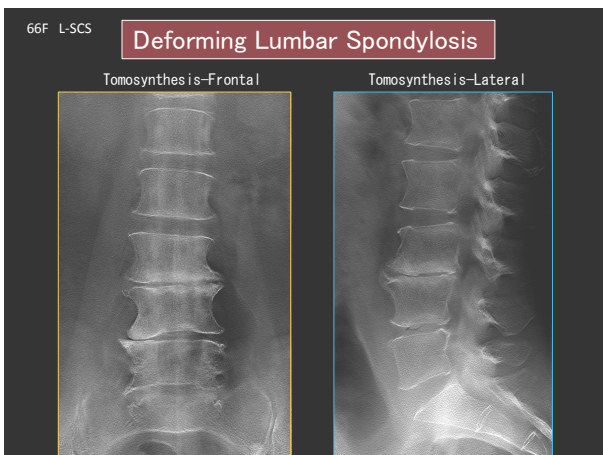


Fig. 8

**Fig. 8** shows a case of lumbar spondylosis. The

disc changes, the formation of osteophytes, and so on, can be adequately determined using plain radiography, in the same manner as for cervical spondylosis mentioned above, but TS shows changes in sclerotic line, osteophytes, disc shape, endplates, and especially cortical bone shape particularly well in the frontal view. The fact that endplates are visible in TS frontal images of spondylosis means spondylodiscitis changes can be seen very clearly, although this patient is not the case. Another major advantage of TS is being able to see detailed morphology of sclerotic line in modic classification.

Next we will consider lumbar spondylolysis (**Fig. 9a** and **9b**). Spondylolysis can be determined using plain radiography, if observed carefully, but TS shows differences in separation on the right and left and the relationship between the separation and the spinal canal. Of course, a more accurate understanding can be obtained using CT, but TS is recommended if there is uncertainty in plain radiography. If spondylolysis is suspected in young patients, then the low X-ray exposure level of TS is a significant advantage. It is also important to obtain the large amounts of information provided by TS, such as determining the location of spondylolysis, degree of change in discs or endplates, and degree of spondylolisthesis, before using CT.

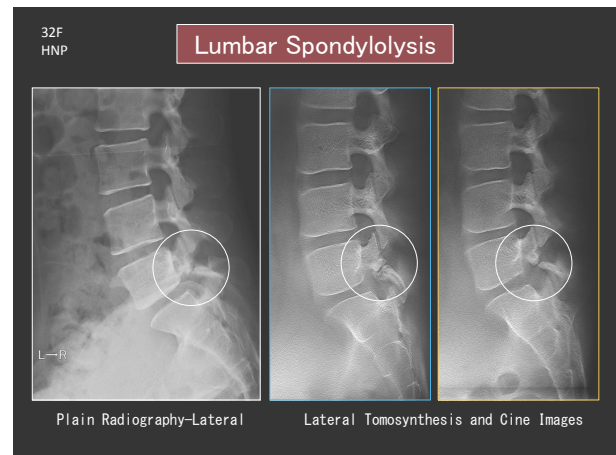


Fig. 9a

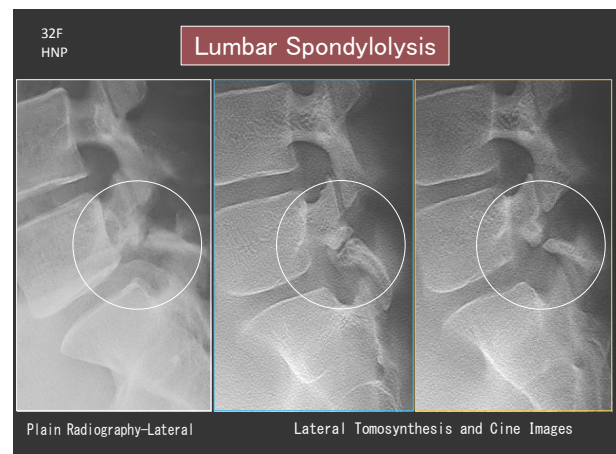


Fig. 9b Enlargement of Fig. 9a



A comparison of CT, which is able to obtain 360 degrees of data, and TS, which is only able to obtain 40 degrees of data, shows a significant difference and the superiority of CT (Fig. 10). Nevertheless, after plain radiography, TS could also be useful for providing a guideline for determining where to focus the CT scan.

Though not shown here, TS also shows changes in sacral lesions very well. The summary information for lumbar vertebrae is the same as indicated for cervical vertebrae (Fig. 11). TS is excellent for rendering spondylolysis, vertebral body fractures, osteophytes, vertebral body fusion, vacuum phenomena, and so on, and also would be good for confirming positions. Though TS is positioned somewhere between plain radiography and CT, it is often sufficient for making a determination. If used effectively, TS offers the advantage of being able to reduce X-ray exposure of CT while still adequately rendering trabecula.

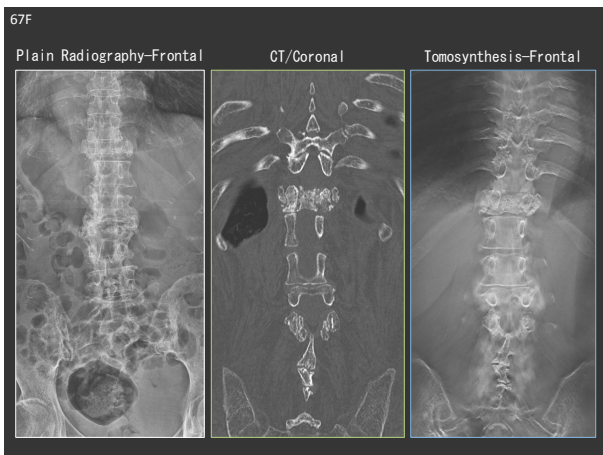


Fig. 10

87th Annual Meeting of the Japanese Orthopaedic Association—Evening Seminar 4

Summary for Lumbar Vertebrae			
	Plain Radiography	TOMOS	CT
Fine Detail	×	○	◎
3D Visualization	×	○	◎
Axial Images of Spine	×	×	◎

(It provides both right and left sides of vertebrae with single scan but no axial images.)

- Excellent rendering of sacral vertebra lesions, etc.
- Excellent rendering of lumbar spondylolysis, vertebral body fractures, osteophytes, vertebral body fusion, vacuum phenomena, etc.
- Also good for rendering trabecula

Fig. 11

### 3. Application of T-smart

So far, I have talked about applications associated with rendering lesions, but next I will discuss the

most useful applications for T-smart. T-smart is most useful for viewing bone fusion, pedicle screw loosening, and so on, in instrumentation surgery. I will also discuss using it for determining the fusion of bone grafts inside PLIF cages.

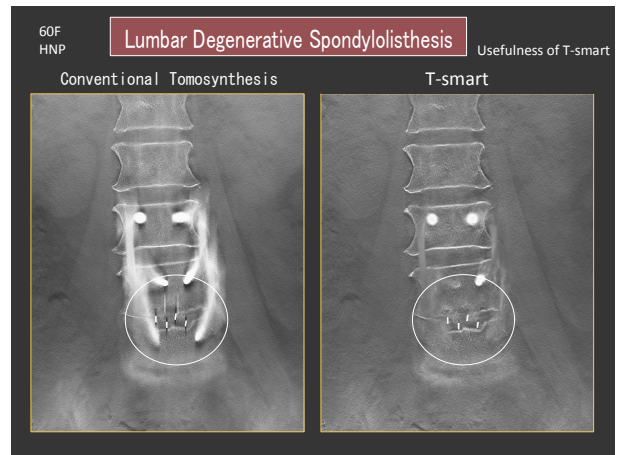


Fig. 12

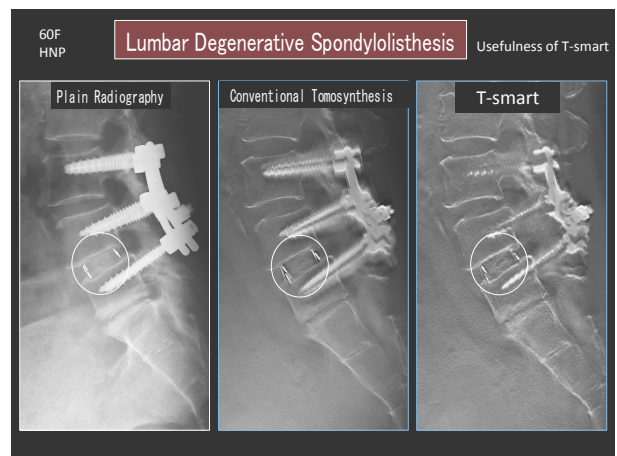


Fig. 13

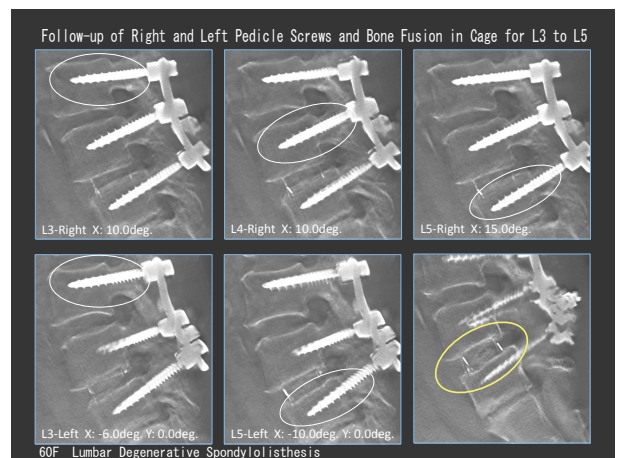


Fig. 14

First, I will use an example of lumbar degenerative spondylolisthesis to describe differences between conventional TS and T-smart (Fig. 12, 13, and 14). The T-smart image shows almost no metal artifacts. However, this is not available at just any facility. By

working with Shimadzu to devise various innovations and modifications, so that we can routinely obtain these types of images, we are extremely hopeful that we can distinguish between screw artifacts and loosening without using CT. However, even conventional TS can be quite useful compared to plain radiography, which cannot be used for these determinations. Also for lateral images, a comparison of conventional TS and T-smart shows how screw artifacts appear very differently, with T-smart showing that there is no loosening. T-smart also allows determining the level of bone fusion in the cage in more detail.

Next we will consider a case of PLF (**Fig. 15**). It is quite difficult to see the bone fusion using plain radiography. However, there is a reluctance to use CT for only that purpose, due to the higher X-ray exposure levels. Using TS (with T-smart) allows anyone to see at a glance that the bones have completely fused.

It is quite difficult to determine vertebral body fusions using only plain radiography, but using a frontal TS image allows making the judgment with almost complete certainty. In other words, a single TS scan can be used to determine both PLF and vertebral body fusion.

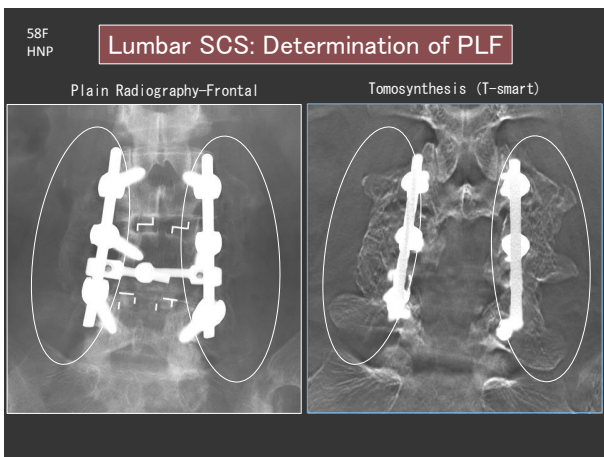


Fig. 15

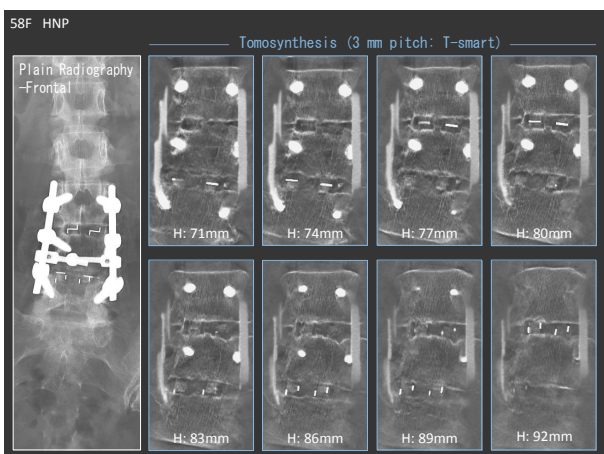


Fig. 16

**Fig. 16** shows a series of image slices 3 mm apart. There are almost no artifacts of the vertebral body cage, allowing more detailed bone fusion determination. Obviously, lateral plain radiography of extension/flexion would be used to determine bone fusion, but TS images provides extremely useful information about bone fusion if obtained at 3, 6, or 12 months after surgery. Based on the above, criteria could probably be generated for using TS to evaluate screw artifacts, degree of screw loosening, and the status of bone fusion.

**Fig. 17a** and **17b** show a case of screw loosening. In this case, loosening is evident to a certain degree even in plain radiography, but the key point for diagnosing screw loosening with CT and TS is not simply the radiolucent zone surrounding the screw, but also the sclerotic line around that area. The jagged image of sclerotic line around the screw and the black radiolucent zone immediately outside that area probably are not due to loosening.

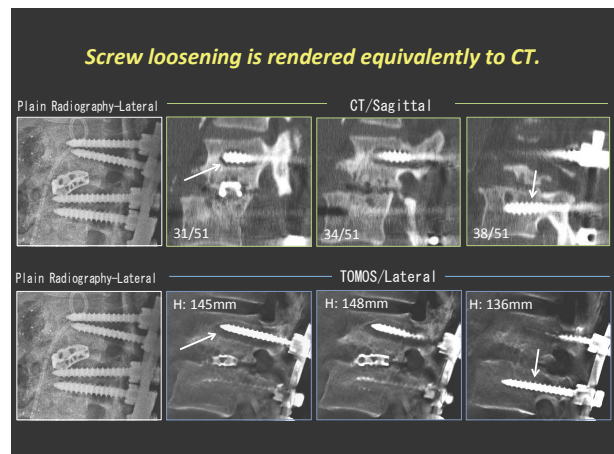


Fig. 17a

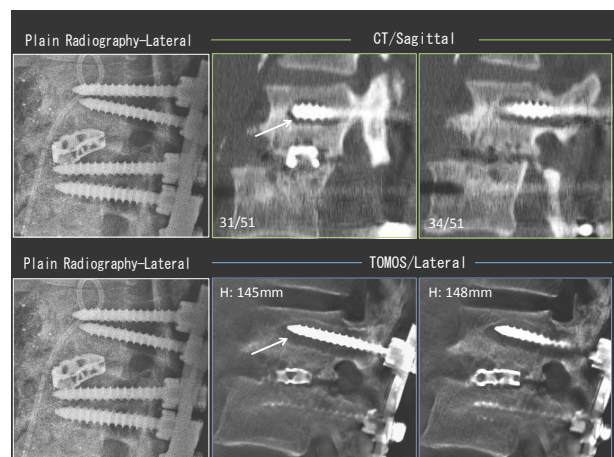


Fig. 17b Enlargement of Fig. 17a

Loosening is apparent from the large radiolucent zone surrounded by sclerotic line also in the frontal image (**Fig. 18a** and **18b**).



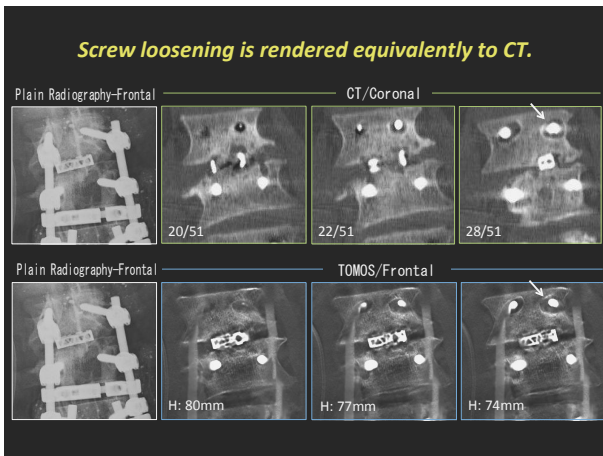


Fig. 18a

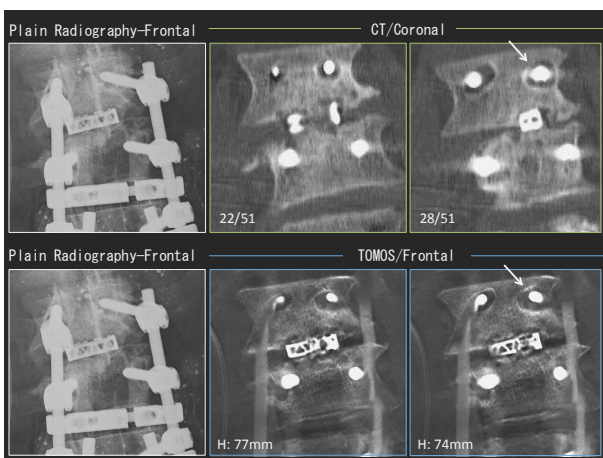


Fig. 18b Enlargement of Fig. 18a

On the other hand, in this case CT clearly shows the complete bone fusion inside the cage. Now that cages are mostly made of PEEK, rather than metal, determination of bone fusion by TS is even easier than before.

Fig. 19 shows a different case, where the visibility of screw loosening is approximately equivalent with CT and TS.

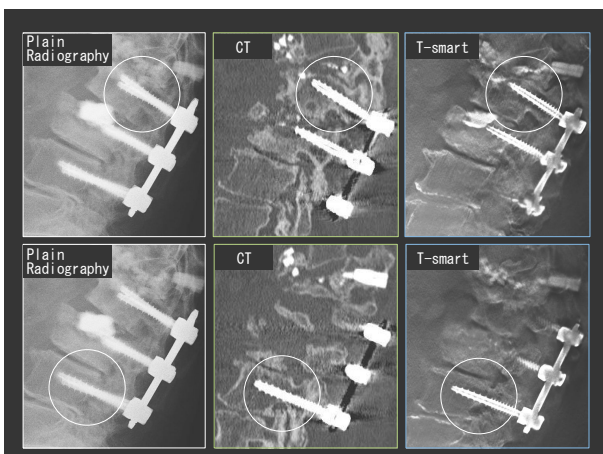


Fig. 19

To summarize up to this point, TS (with T-smart) allows making bone fusion decisions for lumbar fixation far more easily than plain radiography. It even shows the trabecula in bone grafts. The interface between the upper/lower edges of the vertebral body and the bone graft can also be identified. The fact metal artifacts can be suppressed is an especially big benefit. It shows screw loosening almost as well as CT. However, in the case where metallic cages are used, it is important to judge the bone fusion with care, due to possibility of residual images arising from the metal (Fig. 20).

### Bone Fusion of Lumbar Fixation

1. Easier to determine bone fusion than with plain radiography.
  - 1) Posterior lumbar fusion  
⇒ It shows even trabecula of bone grafts.
  - 2) Posterior lumbar interbody fusion  
⇒ It also visualizes the interface between upper/lower edges of vertebral body and bone graft.  
⇒ It suppresses metal artifacts.
2. Identification of screw loosening is about equivalent to CT.

Note: It can leave residual images from right/left cages in some cases.

Fig. 20

In the other example, which compares frontal images obtained by plain radiography, CT, and TS (with T-smart), there is no significant difference. However, unfortunately, residual images of the long vertical rods appear even with T-smart (Fig. 21). In the lateral view, the rods do not obstruct visibility of screws very much, but due to the difficulty eliminating the residual rod images in the T-smart frontal view, that area cannot be evaluated for screw loosening. Needless to say, it is far better than plain radiography, but this is probably the best that can be achieved with T-smart.

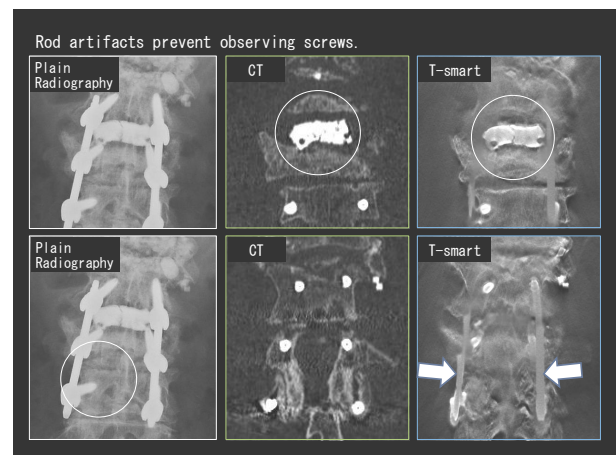


Fig. 21

In contrast, this metal artifact of CT is so prominent, it is difficult to judge the status of bone fusion inside the cage, as shown in the TS and CT comparison in **Fig. 22**. The TS images clearly show that the bones have fused. Although we must experience more similar cases before making an evaluation, there are cases where TS is clearly superior to CT. For a comparison of these imaging technologies, we also need to consider the difference in X-ray exposure levels of each. In frontal images of the same case (**Fig. 23**), the T-smart image may include rod artifacts, but shows the bone fusion inside the cage, which is difficult to determine using CT. CT offers the advantage of being able to reconstruct 3D images, but it also has issues with X-ray exposure level and in some cases cannot completely eliminate some artifacts (neither can T-smart). Therefore, it is important to use T-smart as effectively as possible when viewing loosening and bone fusion.

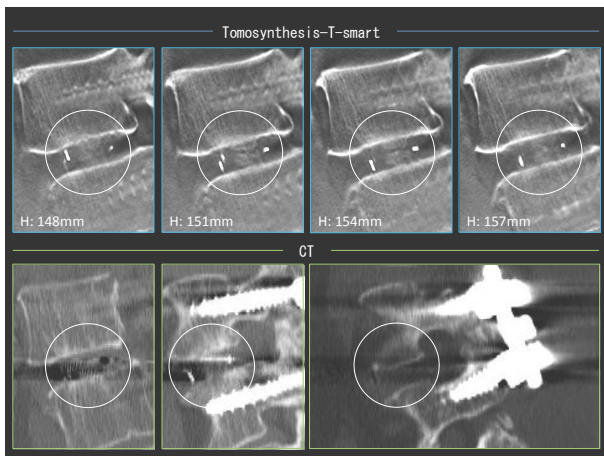


Fig. 22

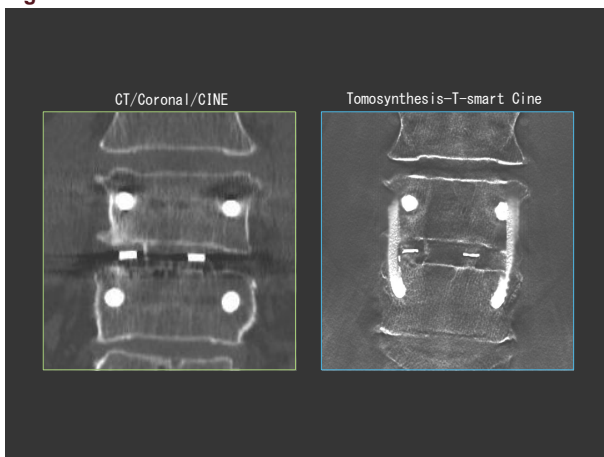


Fig. 23

#### 4. SLOT Radiography

Next, we will consider SLOT radiography for scoliosis and other cases. SLOT radiography is performed from the top to the bottom of the imaging area, with the tube and detector moving in parallel so that the entire image is projected from the direction

perpendicular to the patient. In the past, when using auto-stitching with conventional long-view radiography for the entire spine in the supine position, sometimes the patient was laid on the floor to achieve a long enough focal length, but SLOT radiography makes the process much more convenient. With conventional methods, X-rays are projected at an angle and this causes overlapping between vertebral bodies and discs, which could make it difficult to diagnose vertebral fractures. However, SLOT radiography projects the X-rays through the spine parallel to all vertebrae, so that vertebral fractures can be evaluated more accurately and easily. SLOT radiography also makes it easier to evaluate scoliosis before and after surgery. This example shows that the X-rays pass through all the intervertebral spaces (**Fig. 24**). This is the key point about SLOT radiography.

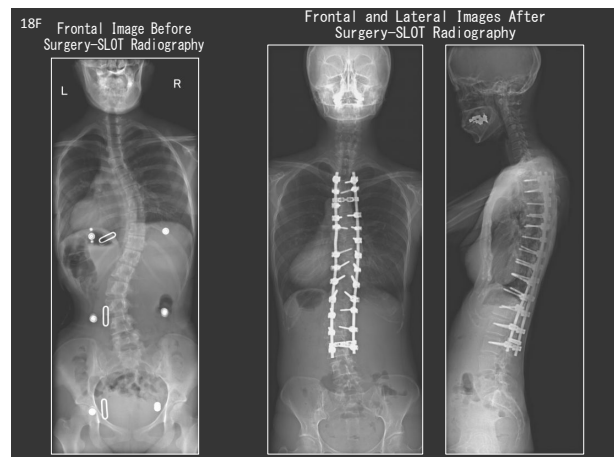


Fig. 24

In this case, SLOT radiography was used to capture the entire spine and TS (with T-smart) was used to evaluate the screws. However, for long fusion cases such as this, TS cannot be used to view the entire spine from one scan, so two scans are required (**Fig. 25**). The bone fusion is a little difficult to see, but in some cases even bone fusion for posterior fixations are visible. As shown here, the utility of TS is very high even for scoliosis.

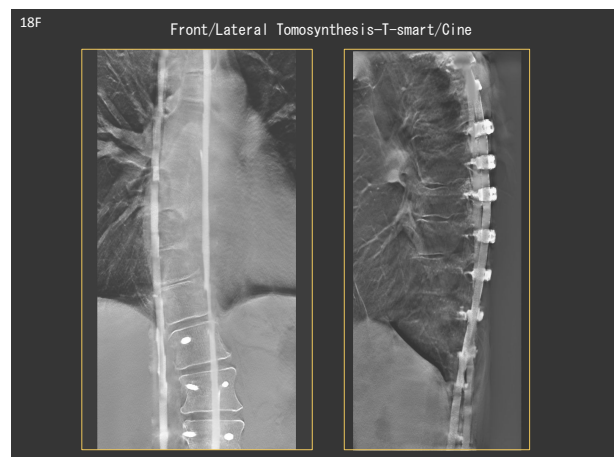


Fig. 25

## 5. Using TS for Measurements of Sagittal Spino-Pelvic Alignment

Lastly, I will briefly discuss some of the research we are working on. This shows images obtained by plain radiography and TS in the standing position and by CT in the supine position (Fig. 26). TS and SLOT radiography was used for the measurements of sagittal alignment (Fig. 27).

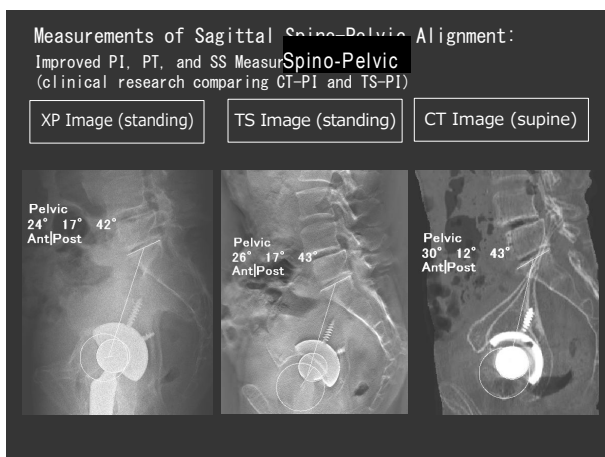


Fig. 26

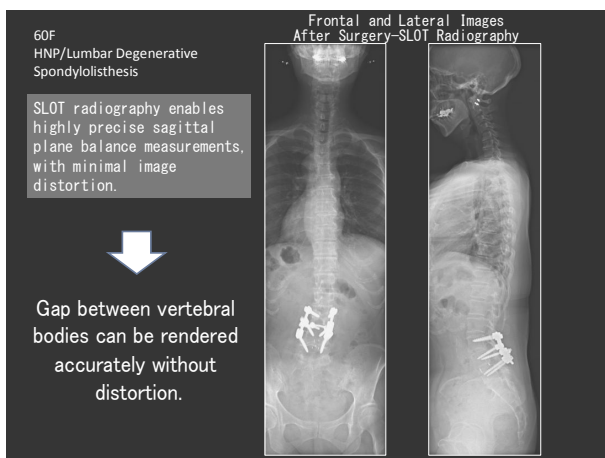


Fig. 27

The case shown in Fig. 26 has a total hip arthroplasty (THA) on one side. The opposite hip joint is not visible with plain radiography. However, due to the large number of cross sectional images obtained by TS, the opposite hip joint is visible as well. (For measurement purposes, hip joint images from both sides and spine images were combined for these TS and CT images.) As shown here, when measuring the pelvic incidence (PI) or lumbar lordosis (LL) of the sacral slope (SS) in sagittal alignment, even the sacral table may not be visible in some cases using plain radiography. In such cases, TS has a big advantage of providing precise morphological information for drawing measurement lines. Using accurate lines allows

measuring angles accurately. Actual cases will be presented at future conferences. Consequently, TS is useful for the measurements of sagittal alignment.

## 6. Remaining Issues

In terms of remaining issues for TS, TS generates large amounts of data that cause slow display speeds, which can be annoying. Therefore, to minimize delays, using smaller fields of view would be effective. Even with T-smart, long vertical metal objects, such as PLIF rods, can leave artifacts, which can be a problem to check screws in frontal PLIF images. Though T-smart is very useful, it takes several minutes to reconstruct images, which can cause technologists to scream with frustration if a large number of examinations are reconstructed using T-smart (Fig. 28). Therefore, we would appreciate some improvements in that area as well.

### Tomosynthesis Issues

- Display is slow, due to the large image data.
- Use as small FOVs as possible for tomosynthesis. In general, use the 9-inch FOVs. (It also helps reduce X-ray exposure.)
- The artifacts from vertical long metals, parallel to X-ray tube travel direction, are difficult to eliminate even with T-smart. (T-smart resolves problems with artifacts caused by long metal objects in the transverse direction, such as PS.)
- Screw loosening is difficult to determine if rods and screws overlap in frontal PLIF tomosynthesis.
- T-smart is very useful, but image reconstruction is slow (several minutes), which may affect examination efficiency.

Fig. 28

## 7. Concluding Comments

TS, including T-smart, has become more useful than traditional tomography. As mentioned in the beginning, there is likely a TS system already available at your medical facilities. It would be a shame to let it go to waste without even knowing it is available. I also hope my presentation may have been helpful to doctors considering purchasing a new system. This presentation focused primarily on the spine, but TS can be used for many other applications as well, such as joints and fractures. That ends my presentation.

Thank you for listening.